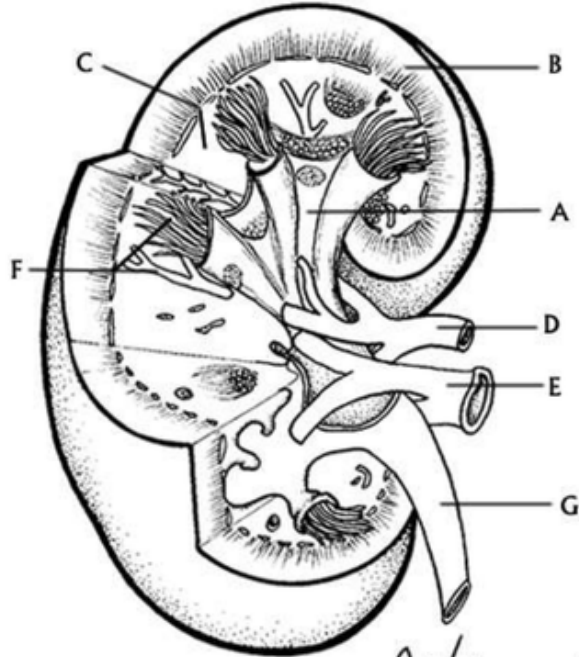


Name: _____ Date: _____

STRUCTURE OF THE NEPHRON



RENAL PELVIS_A
 CORTEX_B
 MEDULLA_C
 RENAL ARTERY_D
 RENAL VEIN_E
 NEPHRON_F
 URETER_G

BOWMAN'S CAPSULE_H
 GLOMERULUS,
 DISTAL TUBULE_K
 PROXIMAL TUBULE_L
 LOOP OF HENLE_M
 CAPILLARIES_N
 COLLECTING DUCT_O

