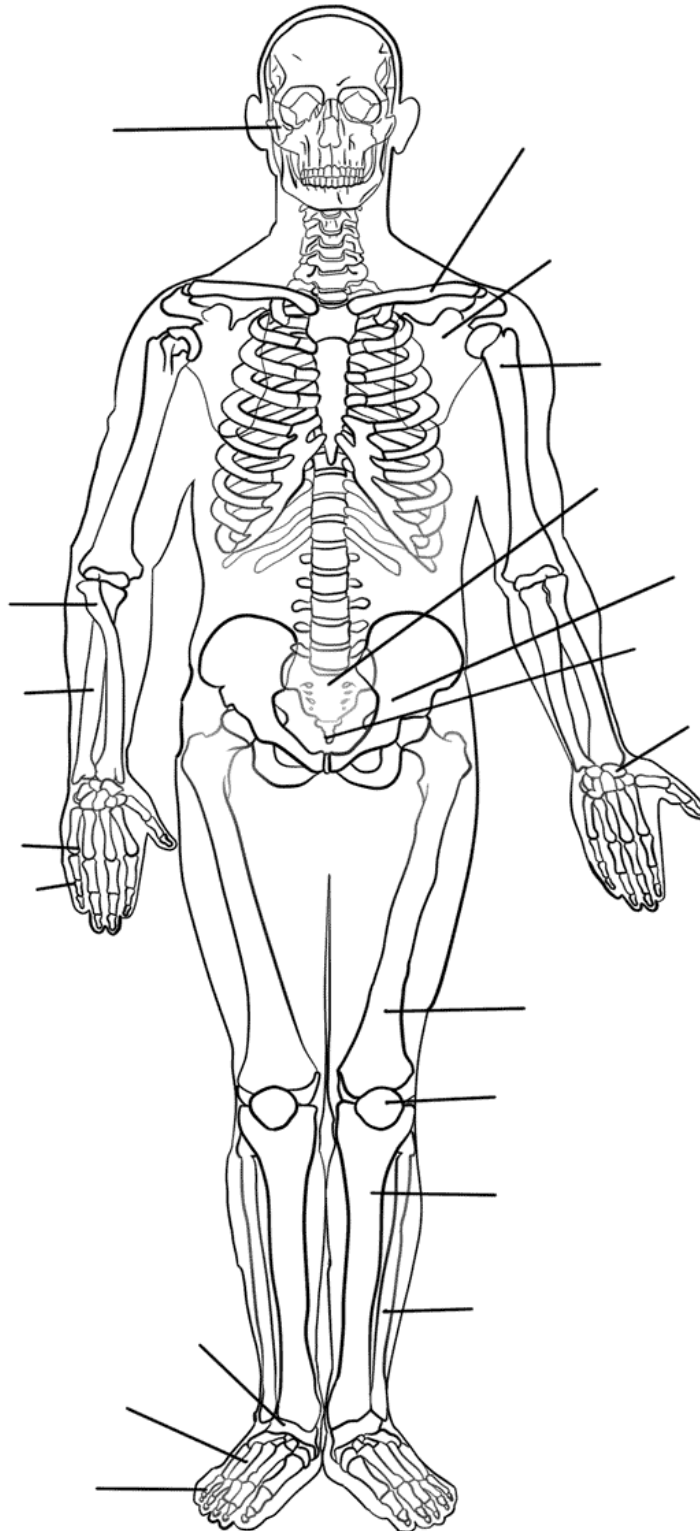


Human Skeletal System



Word Bank

- | | | | |
|--------|----------|--------------|-------------------|
| Ulna | Patella | Humerus | Carpal bones |
| Tibia | Scapula | Hip bone | Auditory ossicles |
| Fibula | Sacrum | Phalanges | Metatarsal bones |
| Femur | Coccyx | Phalanges | Metacarpal bones |
| Radius | Clavicle | Tarsal bones | |

